



30<sup>th</sup> May, 2017

Dr. Mala Mani

Review Editor

*Journal of Visualized Experiments*

Dear Dr. Mani,

**Manuscript#: JoVE56137**  
**Using Retinal Imaging to Study Dementia**

Thank you very much for the review of the above manuscript. We are pleased to address the comments raised in the review and have included the Reviewers' suggestions in the enclosed revised manuscript. The changes/additions in the revised manuscript are identified in the track changes. The current word count is 7,427 for the text of the manuscript and 143 for the long abstract.

**Editorial Comments:**

***1) The Protocol should contain only action items that direct the reader to do something. Please move the discussion about the procedure to the Results or Discussion section. "Notes" should be concise and used sparingly. They should only be used to provide extraneous details/optional steps/recommendations that are not critical to a step. Please move Sections 2, 3 and 4 NOTES to the results or discussion sections.***

**Authors' response:**

Thank you. Most "Notes" have now been moved to the results or discussion sections, unless necessary:

- (1) Two Notes that indicate the pause steps of the protocol
- (2) A note stating that the SIVA program can be substituted by other computer-assisted analysis programs:

- 2.2. Open the images in the computer-assisted analysis program for automatic tracing.

Note: The SIVA program is used for illustration purpose only and can be substituted by other available measurement programs.

- (3) A note that describe the morphological differences between arterioles and venules, which provides details and guidance to step 2.3.2:

- 2.3.2 Left click to select the vessels with incorrect vessel label (arterioles vs venules) and click the "Vessel (T)ype" button to change the vessel type.

Note: Arterioles can be distinguished from venules based on their physiological differences. For e.g. venules are in general darker in color and wider than arterioles. Vessels with same vessel type do not cross each other. Arterioles are labelled in red and venules are labelled in blue.



(4) A note that explain the meaning of “vessel covers”:

- 2.4.1 Click the “Find Covers” button to lay vessel covers on all vessel segments automatically.

Note: Vessel covers are measurement lines that estimate the approximate width of the internal lumens of the vessels.

(5) A note stating that which steps can be automatically done by the computer-assisted analysis program:

- Note: Steps 3.1 to 3.7 can be completed automatically by a computer-assisted analysis program
- Note: Steps 4.2.2.1 to 4.2.2.4 can be automatically completed by the analysis algorithm.
- Note: Steps 4.3.2.1 to 4.3.2.6 can be automatically completed by the analysis algorithm.

(6) A note that explains the size and shape of the elliptical annulus, which is used to assess the GC-IPL thickness.

- Note: The size and shape of the elliptical annulus conform closely to the macular anatomy and thus correspond to the area where the RGCs are thickest in normal eyes<sup>33,34</sup>. The area within the inner ring of the annulus is not measured as the macular GC-IPL in this area is very thin and difficult to detect accurately.

**2) Section 3: Please re-write this in the imperative tense and provide stepwise detail on how to perform the retinal vasculature measurement.**

Authors' response: Thank you. This section has now been re-written in the imperative tense to illustrate the procedures of measuring retinal vasculature. We would like to highlight that the steps described in this section can be completed automatically by the computer-assisted program. Hence, we decided to place more emphasis on the steps of manually adjusting the vessel tracings, instead of providing too much details on this section. The revisions are quoted as follows:

- 3. Measure the retinal vascular parameters using a computer-assisted program.

Note: Steps 3.1 to 3.7 can be completed automatically by a computer-assisted analysis program

3.1 Open the fundus photograph to be measured.

3.2 Place four concentric circles as measurement grids using the centre of optic disc as a reference (Figure 6A). Label the area 0.5-1.0 disc diameters away from the disc margin as zone B, and the area 0.5-2.0 disc diameters away from the disc margin as zone C<sup>18</sup> (Figure 6A), according to the modified protocol of Atherosclerosis Risk in Communities (ARIC) study<sup>19</sup>.

3.3 Measure retinal vascular caliber from both zone B and zone C, using a method modified from the ARIC study<sup>19</sup> (Figure 6B), which has been widely adopted in many large population studies<sup>20-26</sup>.

3.3.1 Measure the lengths of vessel covers in the six largest arterioles and the six largest venules to estimate retinal vessel calibers.

3.3.2 Summarize the retinal arteriolar and venular calibers as central retinal artery equivalent (CRAE) and central retinal vein equivalent (CRVE) respectively<sup>17</sup>, using the revised Knudtson–Parr–Hubbard formula<sup>18,19</sup>.

[Place New Figure 6 Here]

3.4 Identify all vessels in zone C with a width >40 μm. Calculate the retinal arteriolar and venular tortuosity from the integral of the total squared curvature along the vessel paths and normalize the value with the total arc length, bowing, and points of inflection<sup>27,28</sup>.

3.5 Compute the total, arteriolar, and venular fractal dimensions from zone C, using an established method called “box-counting method”<sup>29-31</sup>.

3.5.1 Divide the retinal image into a series of equally sized square boxes.

3.5.2 Count the number of boxes containing a section of the skeletonized line tracing.

3.5.3 Repeat the process with a series of different sized boxes.

3.5.4 Plot the logarithm of the number of boxes containing the line tracing against the logarithm of the size of the boxes, and calculate the slope of the line, which is the fractal dimension.

3.6 Identify vessels with first bifurcation in zone C and calculate the angles (θ) subtended between first two daughter vessels<sup>32</sup> (Figure 6C). Compute the mean value to obtain the average branching angle.

3.7 Calculate the branching coefficient from zone C using the formula:  
 $(d_1^2 + d_2^2)/d_0^2$ , where  $d_0$  is the mean trunk caliber,  $d_1$  and  $d_2$  are the mean branch calibers (Figure 6C).

### 3) Section 4: Please adjust the numbering in this section.

Authors' response: Thank you. The numbering of all sections (including section 4) has now been adjusted.

### 4) 4.1.1.6: Using which similar methods? Please specify the step numbers.

Authors' response: Steps 4.1.1.6 has now been re-numbered into 4.1.6 and revised as follows:

- 4.1.6 Perform an optic nerve head scan with the “Optic Disc Cube” scanning protocol using steps 4.1.2 to 4.1.5 (Figure 7B).

#### 5) 4.1.1.8: Save images as what file type?

Authors' response: Thank you. The images captured by the OCT are normally saved as built-in-program-specific file format and stored within the program. In other words, researchers are not required to choose the file type after the image acquisition process. For this reason, the file type is not specified in the protocol. To avoid confusion, 4.1.1.8 has now been revised as:

- 4.1.8 Save the scanning results.

For your information, steps 4.1.1.8 has now been re-numbered into 4.1.8.

#### 6) 4.1.3: Please re-write this in the imperative tense and provide stepwise detail on how to perform the measurement.

Authors' response:

Thank you. This step has now been revised and renumbered, as follows:

- 4.2. Generate the analysis printout of the macular GC-IPL thickness.

4.2.1 Select the “Macular Cube” scan records of both eyes in the analysis interface

4.2.2 Click the “Ganglion Cell OU Analysis” to initiate the automatic analysis algorithm to assess the GC-IPL thickness of the captured image (Figure 7E).

Note: Steps 4.2.2.1 to 4.2.2.4 can be automatically completed by the analysis algorithm.

4.2.2.1 Generate a 14.13 mm<sup>2</sup> fovea-centered elliptical annulus, which has horizontal inner and outer radius of 0.6mm and 2.4 mm respectively, and vertical inner and outer radius of 0.5 mm and 2.0 mm respectively.

Note: The size and shape of the elliptical annulus conform closely to the macular anatomy and thus correspond to the area where the RGCs are thickest in normal eyes<sup>33,34</sup>. The area within the inner ring of the annulus is not measured as the macular GC-IPL in this area is very thin and difficult to detect accurately.

4.2.2.2 Segment the outer boundary of the RNFL and the outer boundary of the inner plexiform layer (IPL) to locate the GC-IPL (Figure 9).

4.2.2.3 Measure the (a) average, (b) minimum and (c) six sectorial (superotemporal, superior, superonasal, inferonasal, inferior, inferotemporal) thickness of macular GC-IPL within the fovea-centered elliptical annulus.

4.2.2.4 Report the measurement results on an analysis printout

4.2.3 Save the analysis printout as pdf format.



[Place New Figure 9 Here]

#### 4.3. Generate the analysis printout of the RNFL thickness (Figure 7F)

##### 4.3.1 Select the “Optic Disc Cube” scan records of both eyes in the analysis interface

4.3.2 Click the “ONH and RNFL OU Analysis” to initiate the automatic analysis algorithm to assess the RNFL thickness of the captured image.

Note: Steps 4.3.2.1 to 4.3.2.6 can be automatically completed by the analysis algorithm.

4.3.2.1 Measure the RNFL thickness at each scan point and generate an RNFL thickness map.

4.3.2.2 Identify the optic disc by detecting a dark spot near the center of the scan that has a size and shape consistent with a range of optic disc.

4.3.2.2 Position a calculation circle of 3.46 mm in diameter around the optic disc on the RNFL thickness map.

4.3.2.3 Measure and calculate the (a) global, (b) four-quadrants (temporal, superior, nasal and inferior), and (c) twelve-clock-hour parapapillary RNFL thickness, using the calculation circle as regions of interest (ROI).

4.3.2.4 Compare the measured RNFL thickness to the device’s internal normative age-matched database and generate a deviation map and a significance map.

4.3.2.5 Report the measurement results on an analysis printout

4.3.3 Save the analysis printout as pdf format.

**7) Please highlight 2.75 pages or less of text (which includes headings and spaces) to identify which steps should be visualized to tell the most cohesive story of your protocol steps. Please see JoVE’s instructions for authors for more clarification. Remember that the non-highlighted protocol steps will remain in the manuscript and therefore will still be available to the reader.**

**Authors’ response:** Thank you. Less than 2.75 pages of steps have been highlighted to identify the steps for visualization.

**8) Results: Please confine to the results obtained by the authors in this section. Please move the discussion about other works to the Discussion section.**

**Authors’ response:** Thank you. The results and the discussion section have now been revised accordingly.





9) Please provide scale bars for microscope images if possible.

Authors' response: Thank you. The size of the OCT images and the fundus photographs has been defined in the associated legends, as follows:

- “Figure 2: Optimal and suboptimal fundus photographs. The image quality of fundus photographs directly affects the measurement and analysis of the retinal microvasculature. Hence, quality of fundus photographs must be checked immediately after image acquisition. The image should be discarded if one of these artefacts is observed. **These images were captured using 50-degree fundus camera.**”

Figure 10: An example to show the differences in retinal vasculature between a normal subject and an AD subject.

.....

**These images were captured using 50-degree fundus camera and were analyzed using the method described in the protocol.**

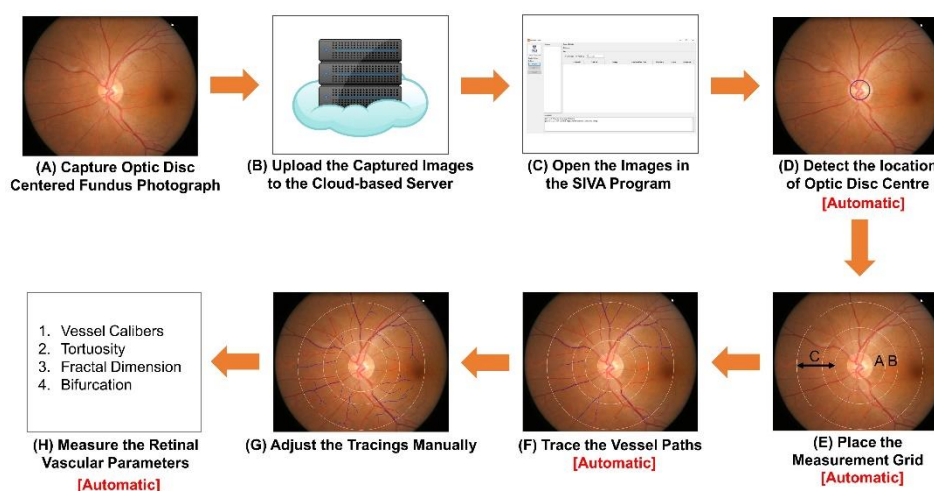
- Figure 11: Analysis printout of the retinal neuronal structure from a subject with AD.

.....

**The scanning area of the images in the analysis printout is 6 mm x 6 mm.**

10) Figure 1: Please replace panel b without the branding “Retina”.

Author's response: Thank you. The figure has now been redrawn as follows:



**11) Figure 7: Please provide a general description of each panel and refer to the panels in the legend.**

Authors' response: Thank you. The legend has now been revised as follows:

- Figure 7: Image acquisition and optimal results of retinal neuronal structure analysis. Optical coherence tomography (OCT) is used to measure the thickness of the ganglion cell-inner plexiform layer (GC-IPL) and retinal nerve fibre layer (RNFL). (A, B): The GC-IPL and RNFL can be imaged using the built-in “macular cube” and “optic disc cube” scanning protocols respectively. (C, D): It is critical to check the image quality immediately after image acquisition. Discard the image and retake the scan if the signal strength is smaller than 6, or motion artifacts are detected. (E, F): After finishing the image acquisition, the built-in algorithm can automatically analyze the image and generate a report for interpretation.

**12) Figure 10: Please provide the values of measurements in the form of a .xls Table. For e.g. the values of average lengths of the vessel, vessel caliber, network parameters, bifurcation geometry, etc. of both normal and AD subjects obtained using your method.**

Authors' response: Thank you. The retinal vascular parameters of both normal and AD subjects in Figure 10 have been included in “New Table 1 (20170530)”.

**13) Figure 10 Lines 605-609 (these finding are...further evaluation): Please move these lines to the results section.**

Authors' response: The legend has now been revised as follows:

- Figure 10: An example to show the differences in retinal vasculature between a normal subject and an AD subject. (A) Fundus photographs of a healthy subject showing wider vessel caliber (CRAE of Zone B, 156.45  $\mu\text{m}$ ; CRVE of Zone B, 207.54  $\mu\text{m}$ ; CRAE of Zone C, 165.82  $\mu\text{m}$ ; CRVE of Zone C, 232.22  $\mu\text{m}$ ), higher retinal vascular fractal dimension (total fractal dimension, 1.517; arteriolar fractal dimension, 1.316; venular fractal dimension, 1.273) and smaller retinal vascular tortuosity (arteriolar tortuosity [104], 0.476; venular tortuosity [104], 0.501). (B) Fundus photographs of an AD subject showing narrower vessel caliber (CRAE of Zone B, 116.38  $\mu\text{m}$ ; CRVE of Zone B, 186.93  $\mu\text{m}$ ; CRAE of Zone C, 138.47  $\mu\text{m}$ ; CRVE of Zone C, 206.61  $\mu\text{m}$ ), smaller retinal vascular fractal dimension (total fractal dimension, 1.472; arteriolar fractal dimension, 1.246; venular fractal dimension, 1.253) and higher retinal vascular tortuosity (arteriolar tortuosity [104], 0.613; venular tortuosity [104], 1.41). These images were captured using 50-degree fundus camera and were analyzed using the method described in the protocol.

**14) Figure 11: Please refer to panels A and B in the legend.**

Authors' response: Thank you. The legend of Figure 11 has now been revised as follows:

- Figure 11: Analysis printout of the retinal neuronal structure from a subject with AD. The analysis printouts of both GC-IPL and RNFL thickness include three types of thickness



map, namely the thickness map, the deviation map and the significance map. (A) The red and yellow super-pixels in the right deviation map (red arrows) indicate the RNFL thickness of these parts of retina fell outside the 99% or within 95%–99% percentile range, respectively. Consistently, the decreased RNFL thickness of these regions is also indicated by the red and yellow sectors in the two significance maps, namely “RNFL quadrants” and “RNFL clock hours”. While the red sectors indicate the RNFL thickness fell outside the normal range ( $p < 1\%$ ), the yellow sector indicates borderline values ( $1\% < p < 5\%$ ). All together, these maps suggest that the RNFL thickness was reduced in the AD subject. (B) The interpretation of the GC-IPL thickness is similar to that of the RNFL thickness. In the AD subject, the thickness map shows more light blue areas (red arrows), which visualize the thinning of the GC-IPL. In line with this finding, the red and yellow super-pixels in the deviation maps (red arrows) also indicate the thickness of these regions fell outside the 99% or within 95%–99% percentile range, respectively. Reduction of GC-IPL thickness in these regions is also illustrated by the red sectors in the significance map.

**15) Please complete the acknowledgement sentence.**

Authors' response: Thank you. The acknowledgement sentence is now completed, as follows:

- We would like to express our appreciation to School of Computing, National University of Singapore for technical supports.

Please do not hesitate to contact us in case of any concerns. We look forward to a positive decision from *Journal of Visualized Experiments*.

Best regards,

Dr Carol Y. Cheung, on behalf of all co-authors.

Assistant Professor

Department of Ophthalmology and Visual Sciences

The Chinese University of Hong Kong

Hong Kong Eye Hospital

147K Argyle Street, Kowloon, Hong Kong

T: +852 39435831 / F: +852 27159490 / Email: [carolcheung@cuhk.edu.hk](mailto:carolcheung@cuhk.edu.hk)

